

A STUDY OF THE CLINICAL PROFILE AND DIAGNOSTIC MARKERS OF PERINATAL BRAIN INJURY IN NEWBORNS

Sirojiddinova Khiromon Nuriddinovna

Associate Professor of Medical Sciences (PhD) of the Department of Pediatrics №1 and neonatology

Fayzillayeva Malika Sukhrobovna

Rakhimova Shakhnozabonu Sokhibovna

Resident physician of the Department of №1 Pediatrics and neonatology Samarkand State Medical University

<https://doi.org/10.5281/zenodo.20181140>

Annotation: This study analyzes the clinical spectrum of hypoxic-ischemic encephalopathy (HIE) in neonates, focusing on its presentation across different degrees of severity based on the Sarnat staging system. The research evaluates the correlation between intrapartum asphyxia and subsequent neurological manifestations, such as altered consciousness, muscle tone abnormalities, and seizure activity. By identifying key clinical indicators and monitoring progression, the study highlights the critical window for therapeutic hypothermia and other neuroprotective interventions to improve long-term neurodevelopmental outcomes.

Key words: Hypoxic-ischemic encephalopathy, newborns, neonatal asphyxia, neurological symptoms, therapeutic hypothermia.

Аннотация: В данной работе анализируется клинический спектр гипоксически-ишемической энцефалопатии (ГИЭ) у новорожденных с акцентом на проявления различной степени тяжести согласно классификации Сарнат. Исследуется взаимосвязь между интранатальной асфиксией и последующими неврологическими симптомами, такими как изменение сознания, нарушения мышечного тонуса и судорожная активность. Выявляя ключевые клинические индикаторы и мониторируя динамику состояния, работа подчеркивает важность «терапевтического окна» для проведения лечебной гипотермии и других нейропротекторных мер с целью улучшения долгосрочных прогнозов развития.

Ключевые слова: Гипоксически-ишемическая энцефалопатия, новорожденные, асфиксия новорожденных, неврологическая симптоматика, терапевтическая гипотермия.

Annotatsiya: Ushbu ishda yangi tug'ilgan chaqaloqlarda gipoksik-ishemik ensefalopatiya (GIE) ning klinik spektri Sarnat tasnifi bo'yicha turli og'irlik darajalari asosida tahlil qilinadi. Tug'ruq jarayonidagi asfiksiya va undan keyingi nevrologik belgilar, jumladan, ong darajasining o'zgarishi, mushak tonusi buzilishlari va talvasa faolligi o'rtasidagi bog'liqlik o'rganilgan. Tadqiqot asosiy klinik ko'rsatkichlarni aniqlash va holat dinamikasini kuzatish orqali, uzoq muddatli rivojlanish natijalarini yaxshilashda terapevtik gipotermiya va boshqa neyroprotektor choralarni qo'llash uchun "terapevtik darcha"ning muhimligini ko'rsatib beradi.

Kalit so'zlar: Gipoksik-ishemik ensefalopatiya, yangi tug'ilgan chaqaloqlar, chaqaloqlar asfiksiyasi, nevrologik simptomatika, terapevtik gipotermiya.

Introduction. Intrauterine fetal hypoxia occupies one of the first places in the structure of the causes of perinatal diseases and mortality. This pathology, as a rule, is a consequence of placental insufficiency, which accompanies almost all complications of pregnancy - miscarriage,

gestosis, developmental delay or fetal death, premature birth, acute or chronic infection [2,3,10]. Recent epidemiological studies indicate the leading role of brain lesions that occurred during the perinatal period in the further dysadaptation, and in some cases, disability in children. Thus, in the structure of children's disability, lesions of the nervous system account for about 50% [1,5,11]. Thus, 35-40% of disabled children are disabled due to perinatal lesions of the nervous system [4,6]. Therefore, the issues of hypoxic-ischemic encephalopathy remain relevant.

In the scientific community, the study of the diagnosis and clinical consequences of perinatal lesions of the central nervous system (CNS) is actively continuing, and significant progress has been made in studying the mechanisms of development of certain forms of hypoxic - ischemic lesions of the central nervous system in newborns. Previous studies revealed that the central links in the pathogenesis of hypoxic lesions of the central nervous system are both cerebrovascular disorders and metabolic disorders [7,13].

Revealing the dynamics of metabolic disorders in CNS lesions in newborns with CHD remains an urgent task and opens up fundamentally new opportunities both for understanding the pathogenesis and for early diagnosis and correction of identified disorders [8,14,15]. The issues of the features of the clinical, instrumental and laboratory course of hypoxic lesions of the central nervous system in newborns, depending on the gestational age, both in the acute period and in dynamics, as well as the further neuropsychic development of children, remain poorly studied and require additional scientific substantiation [9,12].

Purpose of the study: to establish anamnestic and clinical features of hypoxic lesions of the central nervous system in newborns with different periods of gestation.

Material and research methods. We observed 60 newborns with a gestational age of 28 to 41 weeks with hypoxic-ischemic lesions of the central nervous system (HIE). The children were divided into 3 groups: group 1 of 20 newborns with HIE with gestational age 28-31 weeks, group 2 of 20 newborns with HIE with gestational age 32-37 weeks, and group 3 of 20 newborns with HIE and gestational age 38-41 weeks. The control group consisted of 20 healthy full-term newborns.

At all stages of the study and observation of newborns, a gynecological and obstetric anamnesis was collected, the features of the course of pregnancy and childbirth were studied. The early neonatal period was assessed taking into account data on gestational age, birth weight and length, head and chest circumference, physiological loss of body weight, the state of the child at birth on the Angar scale, the presence of resuscitation measures, and the type of feeding were analyzed. In dynamics, the neuropsychic status of the examined children was assessed. To determine the degree of damage to the central nervous system, a neurosonographic study (NSG) was carried out.

Results and their discussion. According to the results of clinical and instrumental examination, hypoxic lesions of the central nervous system of varying severity were diagnosed: in 14 newborns (in 23,3% of cases) there was a mild central nervous system lesion, in 26 (44,3%) - moderate, and in 20 (33, 3%) severe (Fig1).

The severity of hypoxic encephalopathy was established on the basis of clinical syndromes and examination results according to the following criteria: - for mild degree, cerebral ischemia of the 1st degree (mild), intrapartum hypoxia, mild asphyxia at birth;

excitation of the central nervous system is more common in full-term, depression - in premature, lasting no more than 5-7 days; moderate hypoxemia, acidosis; NSG - no pathological abnormalities;

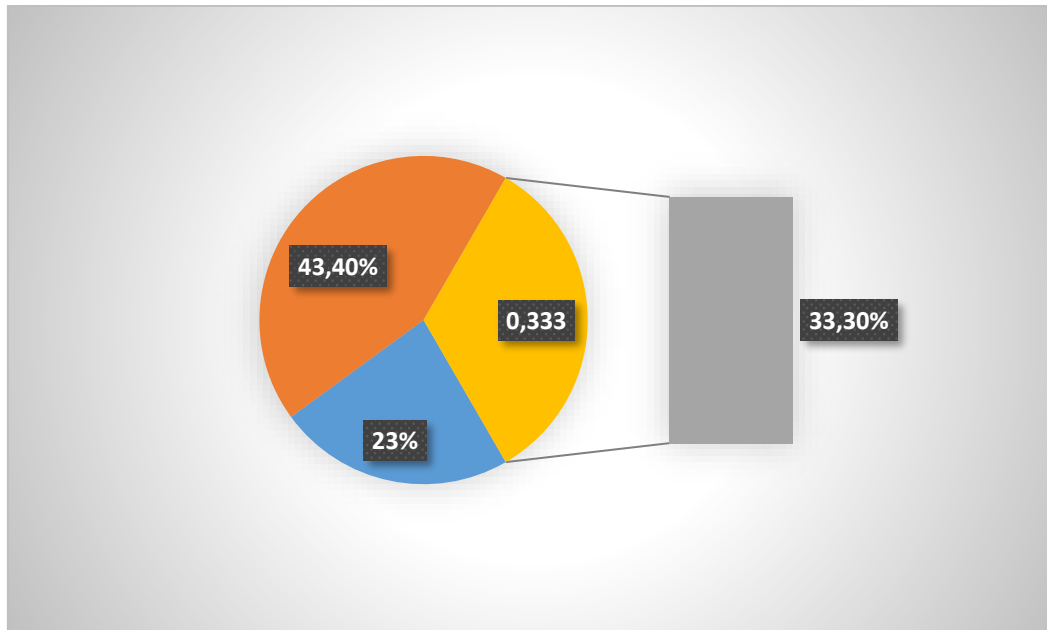


Figure 1. Distribution of newborns with hypoxic-ischemic encephalopathy according to the severity of CNS damage.

for moderate severity: cerebral ischemia of the II stage, the syndrome of suppression of excitation, hypertensive-hydrocephalic syndrome, moderate periventricular edema or IVH of the I stage. on NSG;

- for severe degree: cerebral ischemia grade III, severe depression / excitement syndrome, convulsive syndrome, dense periventricular edema or IVH grade II. on the NSG.

Taking into account that the degree of gestational maturity of the fetus determines both the morphological features of cerebral injury and the spectrum of somatic pathology of the neonatal period, gestational age was used as the main grouping feature in the analysis and presentation of the results obtained. In accordance with the tasks set, the observed newborns were divided into the following groups: group 1 - 20 newborns with HIE with gestational age 28-31 weeks, group 2 - 20 newborns with HIE with gestational age 32-37 weeks and group 3 - 20 newborns with HIE and with a gestation period of 38-41 weeks. The clinical severity of perinatal CNS pathology was analyzed both as an independent factor and in combination with gestational age.

There were no significant intergroup differences in gender composition, although in comparison group I there was a slight predominance of girls. 11 (55%) newborns in group I, 2 (10%) children in group II and 1 child (5%) with intrauterine growth retardation (IUGR) II-III degree in group III had very low birth weight (Fig 2).

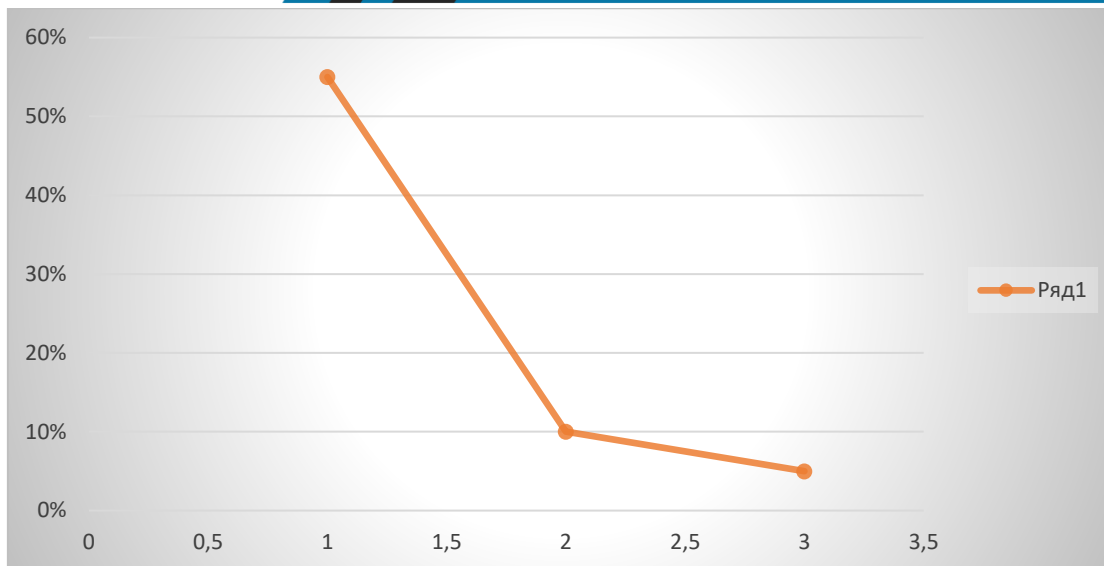


Figure 2. Frequency of observation of cases of very low body weight in the compared groups.

It should be noted that children with extremely low body weight were not observed. In general, the general characteristics of the comparison groups corresponded to the literature data on gender composition, body weight and condition at birth, as well as the frequency of occurrence of lesions of varying severity in children born at different stages of gestation.

The period of early postnatal adaptation was complicated in all children. The condition at birth was assessed as severe in 20 (100%) children of group I, 18 (90%) children of group II, in 12 (60%) patients of group III, respectively (Fig 3).

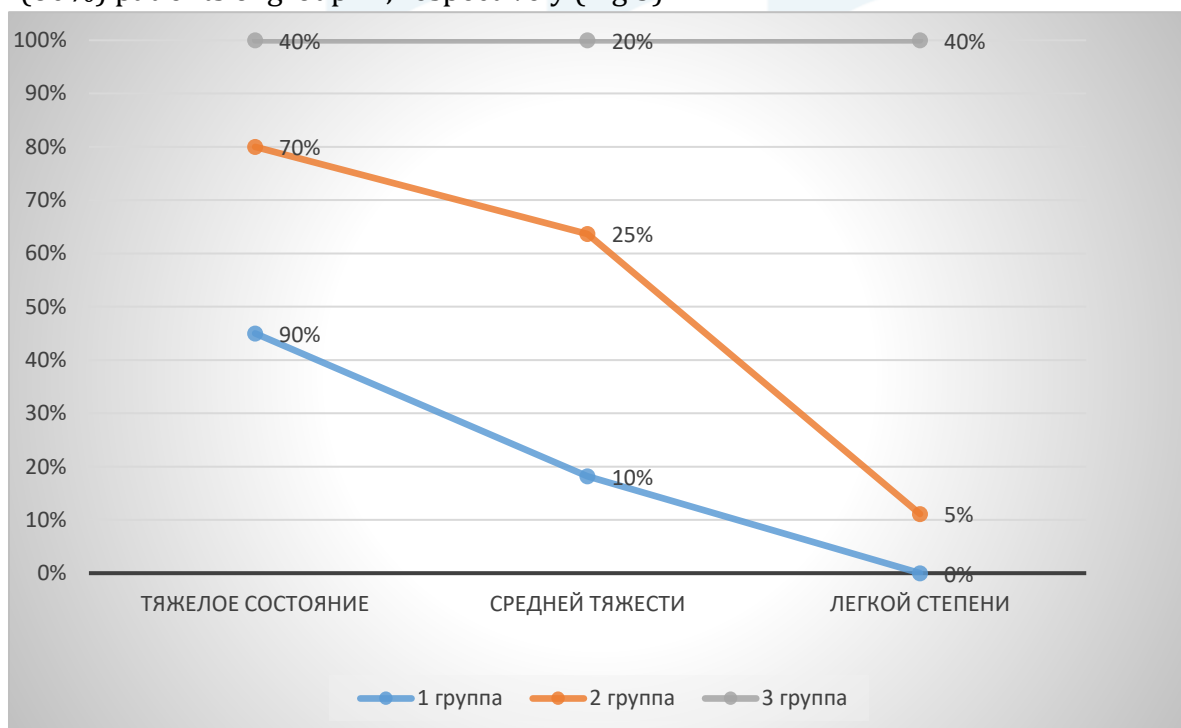

Figure 3. Distribution of newborns in the compared groups according to the severity of the general condition.

The main scale used to determine the assessment of the condition of the newborn and the degree of asphyxia in the child is the Apgar scale. In this regard, during the study, it was found that low scores on the Apgar scale at 1 minute of life were detected in newborns with HIE of all compared groups, but with a greater frequency in newborns of groups 1 and 2 and significantly in relation to both healthy newborns ($p < 0.001$), and to the group of children with HIE but born with a normal gestational age. Neonatal vital activity indices at the 5th minute of life in the 1st group of the study remained at 1-3 points in 50% of newborns, in group 2 this indicator was only 20%, while all children with normal gestational terms with an assessment of 1-3 points showed improvement states.

Apgar score at 1 min. had a significant positive relationship with the gestational age of the child and the severity of subsequently diagnosed perinatal CNS pathology, however, significant differences between the assessments of children with perinatal CNS pathology of varying severity occurred only in group III. So in children of this group with normal weight and gestational age, severe damage to the central nervous system was observed.

Thus, it can be concluded that premature infants with severe HIE have the greatest severe metabolic disorders, which tend to normalize over time, but still significantly differ from the norm. Also, premature infants have more severe shifts in blood gas composition compared to full-term infants with DIE.

CONCLUSIONS

The hypoxic-ischemic nature of the lesion of the central nervous system in newborns depends on the gestational age, the Apgar score and is manifested by oppression syndromes in premature infants, agitation syndromes and hypertensive-hydrocephalic phenomena in full-term infants.

Adabiyotlar, References, Литературы:

1. Aleksandrova V.A. Perinatal lesions of the central nervous system and their consequences in the practice of a pediatrician: a textbook for doctors / V.A. Alexandrova, E.A. Bratova .- SPb., 2021 .- 70 p.
2. Albitsky, V.Yu. Mortality of adolescents in the Russian Federation / V.Yu. Albitsky, A.E. Ivanova, A.G. Ilyin et al. // Russian Pediatric Journal. -2022.-№3.-C.4-10.
3. Amasyants, R.A. Clinic of intellectual disorders: Textbook / R.A. Amasyants, E.A. Amasyants. - Moscow: Pedagogical Society of Russia, 2018. - 320s.
4. Artemieva, I.I. Clinical and biochemical health of perinatal lesions of the central nervous system in newborns / I.I. Artemieva, N.S. Cherkassin // Mother and Child: Materials of the II Russian Forum.-M.-2018.-P.346-347.
5. Afonin, A.A. Dynamics of indicators of cerebral hemodynamics and endothelium of dependent factors of its regulation in children with perinatal CNS damage in the first year. Afonin, V.V. Strogulin, I. G. Loginova, N.A. and others // Pediatrics.-2021.-T. 90.-№ 1.-p.30-33.
6. Bakanov, M.I. Clinical and diagnostic value of enolase and basal myelin in newborns with perinatal hypoxic lesions of the central nervous system / M.I. Bakanov, V.V. Altyrtsev, O.V. Goncharova et al. // Russian Medical Journal.-2023.-No.4.-P. 19-23.
7. Bakanov, M.I. New biochemical criteria for the diagnosis and prognosis of perinatal lesions of the central nervous system in newborn children / M.I. Bakanov, V.V. Alatyrtseva, V.N. Podkopaev // Scientific Center of Children's Health of the Russian Academy of Medical

Sciences-Moscow.-2021.-235p.

8. Baranov, A.A. The state of health of children in the Russian Federation / A.A. Baranov // Pediatrics. 2022.-T. 91.-No. 3.- S. 9-14.
9. Barashnev, Yu.I. Perinatal neurology / Yu.I. Barashnev. - Moscow: Triada-X, 2021.-640 p. 113.
10. Sirojiddinova X.N., Nabieva Sh.M., Ortikboyeva N.T. Intrauterine infection as a developmental factor perinatal pathology // Central asian journal of medical and natural sciences Volume: 02 Issue: 01 | Jan-Feb 2021 ISSN: 2660-4159. On page 107-111.
11. Sirojiddinova X.N., Usmanova M.F., Ortikboyeva N.T., Tuxtayeva M.M. Immunological dynamics of recurrent respiratory infections in frequently sick children on the background of immunocorrective therapy // IJIEMR Transactions, online available on 11 April 2021.Vol 10. On page 131-134.
12. Sirojiddinova X.N., Ikromova Z.X., Nabiyeva Sh.M., Ortikbayeva N.T., Abdullayeva G.D. Metabolic Changes Following Post-Hypoxic Complications in Newborns // International Journal of Current Research and Review DOI: <http://dx.doi.org/10.31782/IJCRR.2020.122229>. Scopus. On page 173-177.
13. Sirojiddinova X.N., Ortikboyeva N.T., Aminova N.A., Akmaljanova A. A. Peculiarities of neurosonography in hypoxic-ischemic encephalopathy in newborns with intrauterine infection // Eurasian journal of academic research. Volume 1 Issue 9, December 2021 ISSN 2181-2020. On page 261-265.
14. Tukhtaeva M.M., Usmanova M.F., Omonova G.Z., Ochilova B.S. Psychomotor changes in hypoxic lesions of the central nervous system in newborns // Eurasian journal of academic research. Volume 1 Issue 9, December 2021 ISSN 2181-2020. On page 271-275.
15. Tukhtaeva M.M., Abduxalik-Zade G.A., Burxonova D.B., Mirkomilova G.M. Clinic - anamnestic characteristic of hypoxic-ischemic encephalopathy in newborns // Eurasian journal of academic research. Volume 1 Issue 9, December 2021 ISSN 2181-2020. On page 261-265.