



DIAGNOSTIC VALUE OF MODERN METHODS OF EXAMINING THE ANTERIOR SEGMENT OF THE EYE IN SECONDARY KERATOECTASIA

KH.M. KAMILOV

<https://orcid.org/0000-0002-7250-8159>

M.S. KASIMOVA

<https://orcid.org/0000-0002-2883-3923>

G.KH. KHAMRAEVA

<https://orcid.org/0000-0002-9375-5482>

D.F. ISMAILOVA

<https://orcid.org/0000-0002-7374-0574>

e-mail: i-diana@mail.ru

Center for the Development of Professional qualifications of Medical
Workers, Department of Ophthalmology, Uzbekistan, Tashkent

<https://doi.org/10.5281/zenodo.14472149>

ARTICLE INFO

Received: 08th December 2024

Accepted: 12th December 2024

Online: 14th December 2024

KEYWORDS

Cornea, keratoconus,
keratoectasia, secondary
keratoectasia.

ABSTRACT

Iatrogenic keratoectasia is a form of keratoectasia that develops as a result of medical procedures or surgical interventions on the cornea of the eye. This complication can occur after operations such as LASIK (laser vision correction), PRK (photorefractive keratectomy), implantation of intraocular lenses and other surgical procedures related to the cornea. Secondary keratoectasia is a serious ophthalmic disease that requires accurate and timely diagnosis in order to choose the optimal treatment. Modern methods of examination of the anterior segment of the eye play an important role in the diagnosis of such conditions, which makes this study relevant and significant for practical ophthalmology. Changes to the cornea can lead to decreased visual function and significant discomfort in patients. The identification and effective treatment of secondary keratoectasias requires accurate and detailed diagnosis.

Iatrogenic keratectasia is a form of keratectasia that develops as a result of medical procedures or surgeries on the cornea of the eye. This complication can occur after surgeries such as LASIK (laser vision correction), PRK (photorefractive keratectomy), intraocular lens implantation, and other surgical procedures involving the cornea.

Secondary keratoectasias are a serious ophthalmologic disease that requires accurate and timely diagnostics to select the optimal treatment. Modern methods of examining the anterior segment of the eye play an important role in diagnosing such conditions, which makes this study relevant and significant for practical ophthalmology. Changes in the cornea can lead to a decrease in visual function and significant discomfort in patients. Determination and effective treatment of secondary keratoectasias requires accurate and detailed diagnostics. In this



context, it is important to use modern methods of examining the anterior segment of the eye, such as keratotopography, anterior optical coherence tomography and endothelial microscopy. These methods provide accurate and objective information about the structure of the cornea, its thickness and surface. With the help of such methods, it is possible to determine the presence and nature of changes, objectively assess their degree and dynamics, and predict treatment results. This is especially important when choosing the optimal treatment tactics and monitoring patients at different stages of the treatment process.

The aim of the study is to evaluate the diagnostic value of modern methods of imaging the anterior segment of the eye in secondary keratoectasias, in order to improve diagnostics.

Material and methods

The study included patients (68 patients) diagnosed with iatrogenic keratoectasia, patients were selected based on clinical manifestations and preliminary examination results. All patients underwent a complete ophthalmological examination, including vision measurement, anterior segment biomicroscopy, intraocular pressure determination, and fundus examination. Modern imaging techniques were used to assess the condition of the anterior segment of the eye and diagnose keratoectasias, such as: Keratotopography: allows you to evaluate superficial changes in the cornea and identify areas of ectasia.

Anterior segment optical coherence tomography (OCT): provides a detailed image of the anterior segment structures of the eye, including the cornea, anterior chamber, and iris.

Corneal confocal microscopy: allows you to obtain high-quality images of corneal epithelial cells and deep corneal structures. The obtained data were analyzed using statistical methods to assess the diagnostic value of each of the anterior segment imaging methods in secondary keratoectasias.

Results

The obtained data were analyzed using statistical methods. Modern methods of anterior segment imaging allowed a detailed assessment of the corneal structure, identification of changes characteristic of keratoectasias, and improved diagnostics of these conditions.

At the initial consultation, patients with keratoectasias complained of various symptoms and sensations. Deterioration of vision: gradual or rapid deterioration of vision, especially when using glasses or contact lenses 85%. Distortion of visual images: occurrence of anomalies in the perception of images, such as double vision, blurring, or distortion of contours 87.3%. Feeling of discomfort: feeling of sand in the eyes 65.5%, feeling of dryness 95%. Feeling of tired eyes, when reading, working at the computer, or in low light conditions 93%. Increased sensitivity of the eyes to bright light 96%. When examining the refraction of patients before refractive surgeries, mild myopia was found to be 8% (9 eyes), moderate myopia was 18% (19 eyes), high myopia was 28% (30 eyes), moderate myopic astigmatism was 17% (18 eyes), and high myopic astigmatism was 29% (31 eyes). In patients who underwent LASIK surgery and photorefractive keratectomy, autorefractometry indices improved to the level of emmetropia and mild myopia.

Number of patients who developed secondary keratectasia: 15 patients within 1 year, 43 patients within 2 to 10 years, 10 patients from 11 to 17 years. At the initial visit, patients with keratectasia complained of: deterioration of vision in 94.1% of cases (64 eyes), redness of the



eyes in 86.8% (59 eyes), allergic reactions in 33.8% (23 eyes), intolerance to spectacle correction in 88.2% (60 eyes) of cases.

During visometry it was revealed that in 84.5% of cases (93 eyes) visual acuity before the operation averaged from 0.04 to 0.09. In 13.6% of cases (15 eyes) visual acuity was from 0.1 to 0.2, and only in 1.8% of cases (2 eyes) - from 0.3 to 0.6. After keratorefractive surgeries, visual acuity in 40% of cases (44 eyes) improved to 0.9-1.0, in 32.7% of cases (36 eyes) - to 0.7-0.8, in 15.4% of cases (17 eyes) - to 0.5-0.6, and in 10% of cases (11 eyes) - to 0.3-0.4. In 1.8% of cases (2 eyes) visual acuity did not change (see Table 1).

Table 1. Dynamics of visual acuity in patients with refractive anomalies before and after surgery

Visual acuity	Before surgery (n=110)		After surgery (n=110)		After a certain time after surgery, with the development of keratoectasia (n=110)	
	Abs.	%	Abs.	%	Abs.	%
0,01-0,09	93	84,5	-	-	58	52,7
0,1-0,2	15	13,6	2	1,8	25	22,7
0,3-0,4	1	0,9	11	10	13	11,8
0,5-0,6	1	0,9	17	15,4	5	4,5
0,7-0,8	-	-	36	32,7	9	8,18
0,9-1,0	-	-	44	40	-	-

Changes in visual acuity after a certain time after refractive surgeries from 0.01 to 0.09 were detected in 52.7% of cases, from 0.1 to 0.2 in 22.7%, from 0.3 to 0.4 in 11.8%, from 0.5 to 0.6 in 4.5%, from 0.7 to 0.8 in 8.18%. At the same time, VA above 0.9 was not detected.

Autorefractometry in patients with keratoectasias revealed myopic refraction in 38.1% of cases, moderate myopic astigmatism in 31.8%, and high myopic astigmatism in 30% of cases.

After refractive surgeries, the radius of curvature in the cornea flattens, which entails an increase in mechanical stress in the corneal stroma. These stresses can lead to the development of ectasias.

Table 2. Keratotopography data of patients with keratectasia

Indicators	Group 1 (patients with keratoectasia)	2-group (healthy people)
K1 (in diopters)	48,2±12,1	43,3±1,66
K2 (in diopters)	47,3±6,3	42,35±1,77
K Max (in diopters)	49,3±4,6	43,4±1,65
Thickness at thinnest point	519±132	545,93±35,9
Distance from the apex to the thinnest point	0,92±0,65	0,66±0,7
Minimum radius of curvature of the cornea (mm)	6,3±0,82	7,72±0,35
Progression index, min	1,93±1,05	0,55±1,01
Progression index, average	2,16±2,8	0,88±1,5

Progression index max	2,36±1,62	0,93±1,4
-----------------------	-----------	----------

As a result of the analysis of the keratotopography of patients with keratoectasia and healthy people, the indicators specified in the table above were obtained. Comparing the results between the two groups, it can be noted that in the group of patients with keratoectasia, increased values of the k1, k2 and k max indicators are observed compared to healthy people. This indicates a change in the shape of the cornea and the presence of keratoectasia. Also, the thickness at the thinnest point in patients was lower than in healthy people. In addition, the data show that the distance from the apex to the thinnest point in patients with keratoectasia was also greater than in healthy people. Comparing the radius of curvature of the cornea, it can be noted that in patients it is minimal compared to healthy people. This indicates a convex shape of the cornea in patients with keratoectasia.

Finally, the analysis of the progression index showed that it is higher for the patients of the group than for healthy people in all three cases: min, average and max. This indicates the progressive nature of keratoectasia in patients. The data obtained confirm the presence of changes in the shape of the cornea in patients with keratoectasia and emphasize the importance of using keratotopography for the diagnosis and monitoring of this disease.

Optical coherence tomography revealed corneal thinning and ectasia (Fig. 1). Keratotopography data confirmed the presence of keratoectasia. The central corneal thickness (Min) in the initial stages of the disease was $470 \pm 18.4 \mu\text{m}$, in the advanced stage of the disease $412 \pm 26.2 \mu\text{m}$. The difference between the smallest corneal thickness and the largest thickness (Min-Max) was $105 \pm 6.7 \mu\text{m}$. The ratio of the average corneal thickness in the upper and lower sections, respectively (S-I) was $68 \pm 4.8 \mu\text{m}$.

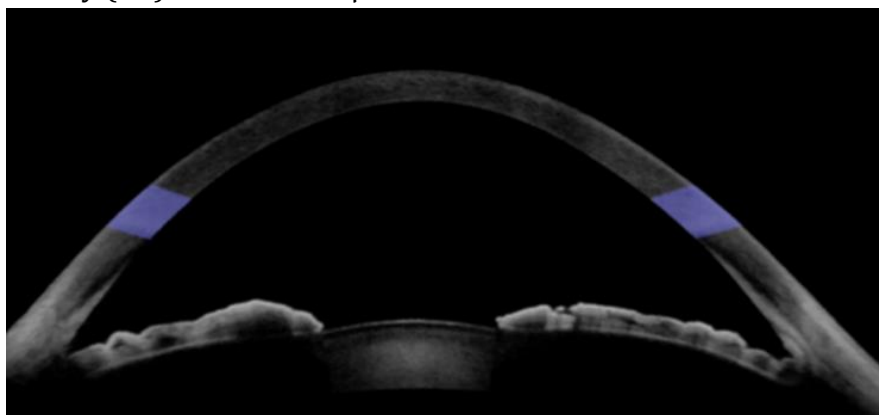


Fig. 1. Anterior optical coherence tomography of a patient with keratoectasia.

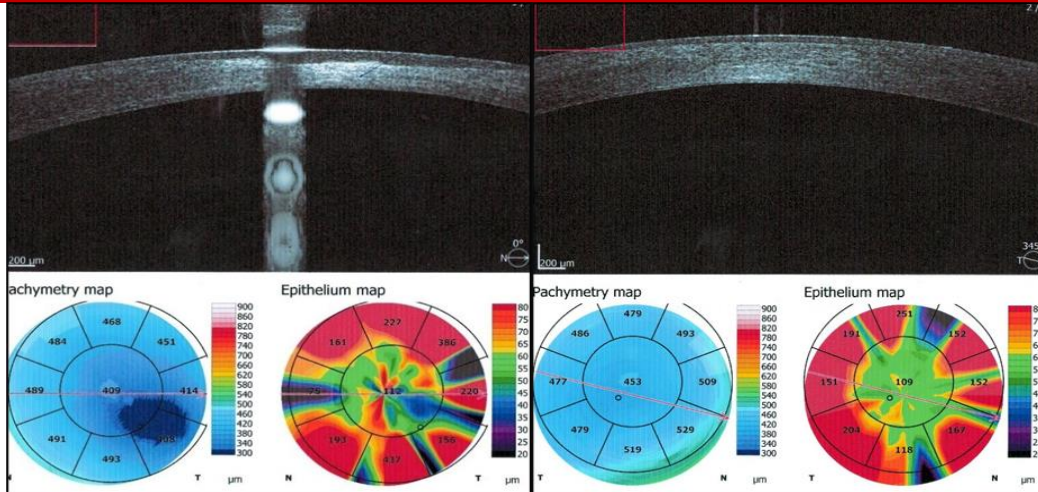


Fig. 2. Results of anterior optical coherence tomography in a patient with secondary keratoectasia.

The results of the study using endothelial microscopy were clinically diverse. The most pronounced changes were observed in the corneal area involved in the ectatic process. In 15 cases, the epithelial layer had various types of epitheliopathy characterized by an increase in the number of hyperreflexive cells, their deformation and blurring of boundaries, and desquamation of epithelial cells. In 16 cases, deformation of the cell shape was determined in the basal epithelium. Small zones were also determined in which the basal epithelium was absent. In 1 patient with pronounced keratoconus, it was not possible to conduct an examination, since the device was unable to scan the cornea (Fig. 3).




Fig. 3. a) The results of endothelial microscopy are normal. b) Results in keratoconus. Moderate polymegatism, pleomorphism and dark areas of endothelial cell loss are visible.

Table 3. The results of endothelial microscopy in the compared groups

Indicators	Indicators of patients with keratoectasia (n=12 eyes)	Healthy individuals (n=10 eyes)
NUM	207±9,4*	281,4±14,78
CD	1189±91,9*	2863,7±54,29
AVG	397±16,2*	349,8±7,1
SD	172,8±13,3*	126,7±7,9
CV	43,1±1,6*	36,3±1,75
MAX	1266±77,1*	819,9±48,4
MIN	91,3±6,3	95,5±3,5



6A	38,1±1,9*	46,5±2,2
CCT	479,3±12,82*	501,8±11,8

Note: * – differences relative to the control group data are significant (*- p<0.05).

Table 3 shows the endothelial microscopy indices in the compared groups.

In keratoectasia, the average loss of endothelial cells was 65% of the norm, while the average endothelial cell density (ACE) was 1189 ± 91.9 cells/mm², with the norm being 2863.7 ± 54.29 cells/mm². This is 58.5% lower than the norm.

Comparative studies of the cornea using endothelial microscopy showed that the number of endothelium (NUM) in patients with keratoconus decreased by 26.3% compared to the control group. The number of endothelium under study per 1 mm² (CD) decreased by 11.8% compared to the control group. The coefficient of fluctuation zone of the endothelium under study (CV) was 15.7% higher in patients with keratoconus than in the control group. The central corneal thickness in patients with keratoconus was 479.3 ± 12.82 Nm², which is 4.5% less than in the control group. A gradual decrease in endothelial cell density after surgery may indicate dystrophic changes in the cornea and the development of keratoectasia.

Conclusion.

Secondary keratoectasia is more often observed after LASIK surgery with the development of myopic refraction (38.1%), myopic astigmatism of moderate (31.8%) and high (30%) degree with flattening of the radius of curvature of the cornea (in 100% of cases).

Keratopography helps to accurately identify ectasias in the lower half-field with reduced pachymetric data, the presence of asymmetric areas of the cornea with protrusion in the lower section and reduced corneal thickness, protrusion on the middle periphery in the lower sections, thinning of the cornea.

Early use of endothelial microscopy allows assessing the condition of the cornea and taking the necessary measures at the early stages of keratoconus. Based on a comparative assessment of the informativeness and sensitivity of the methods, an algorithm of diagnostic measures was created, which includes keratopography - sensitivity 94%, followed in descending order by OCT - sensitivity 92.9%, respectively, as well as endothelial microscopy - sensitivity 92%.

References:

1. Аветисов С.Э. Кератоконус: современные подходы к изучению патогенеза, диагностике, коррекции и лечению. Вестник офтальмологии. 2014;130(6):37–43.
2. Аверич В.В., Егорова Г.Б. Оптические аберрации глаза при кератоконусе. Клиническая офтальмология. 2022;22(3):168–174. <https://doi.org/10.32364/2311-7729-2022-22-3-168-174>.
3. 2022-22-3-168-174.
4. Аветисов С.Э., Новиков И.А., Патеюк Л.С. Кератоконус: этиологические факторы и сопутствующие проявления. Вестник офтальмологии. 2014;130(4):110–116.
5. Абугова Т.Д., Морозов С.Г., Блосфельд В.Б. Новые аспекты проблемы кератоконуса. Глаз. 2004;1:8–13.



6. Аветисов С.Э., Аверич В.В., Патеюк Л.С. Кератоконус: основные направления исследований. Вестник офтальмологии. 2023;139(3.2):11–20. <https://doi.org/10.17116/oftalma202313903211>
7. Балашевич Л. И. Некоторые особенности ранней диагностики кератоконуса / Л. И. Балашевич, А. Б. Качанов, С. А. Никулин // Материалы IV Евро-Азиатской конференции по офтальмохирургии. Разд. II. Екатеринбург, 2006. С. 34-51
8. Камилов Х.М., Касимова М.С., Хамраева Г.Х., Исмаилова Д.Ф. Роль эндотелиальной микроскопии роговицы при диагностике кератоконуса. Передовая офтальмология. 2023;1(1):87-91
9. Егорова Г.Б., Рогова А.Я. Кератоконус. Методы диагностики и мониторинга. Вестник офтальмологии. 2013;129(1):61–66
10. Каспарова Е. А. Ранняя диагностика, лазерное и хирургическое лечение кератоконуса: автореф. дис. д-ра мед. наук / Е. А. Каспарова. М., 2003. 27 с
11. Майчук, О. И. Кондакова // Современные технологии катарактальной и рефракционной хирургии: материалы XI науч.-практ. конф. М., 2010. С. 266-273
12. Asroui L, Mehanna CJ, Salloum A, Chalhoub RM, Roberts CJ, Awwad ST. Comparison of zone averages to single point measurements of maximal curvature in keratoconus. *Am J Ophthalmol.* 2021;221(1):226-234
13. Belin MW, Duncan JK. Keratoconus: the ABCD grading system. *Klin Monbl Augenheilkd.* 2016;233(6):701-707
14. Belin M.W., Ambrosio R.J. Scheimpflug imaging for keratoconus and ectatic disease. *Indian J Ophthalmol.* 2013;61(8):401–406. <https://doi.org/10.4103/0301-4738.116059>
15. Binder P.S., Lindstrom R.L., Stulting R.D. et al. Keratoconus and corneal ectasia after LASIK. *Journal of Refractive Surgery.* 2005;21(6):749–752. <https://doi.org/10.3928/1081-597X-20051101-15>
16. Duncan JK, Belin MW, Borgstrom M. Assessing progression of keratoconus: novel tomographic determinants. *Eye Vis (Lond).* 2016;3:6
17. Belin MW, Alizadeh R, Torres-Netto E, Hafezi F, Ambrósio R, Pajic BP. Determining progression in ectatic corneal disease. *Asia Pac J Ophthalmol (Phila).* 2020;9(6):541-548
18. Pinheiro-Costa J, Rocha-Sousa A, Falcão-Reis F, Brandão EM. Increased choroidal thickness in keratoconus patients: Perspectives in the disease pathophysiology. *J Ophthalmol.* 2019; 2019:245
19. Gunes A, Tok L, Tok Ö, Seyrek L. The youngest patient with bilateral keratoconus caused by chronic constant eye friction. *Semin Ophthalmol.* 2015;30(5-6):454-456
20. Gemonet M, Charpentier P, Muro F. Corneal topography in clinical practice. *J Fr Ophthalmol.* 2019;42(10):e439-e451
21. Gomes JA, Tan D, Rapuano CJ, et al. Global consensus on keratoconus and ectatic diseases. *Cornea.* 2015;34(4):359-369
22. McMahon TT, Anderson RJ, Joslin CE, Rosas G. Accuracy of three corneal topographic instruments in keratoconus. *Optom Vis Sci.* 2001;78(8):599-604
23. Randleman JB, Russell B, Ward MA, Thompson KP, Stulting RD. Risk factors and prognosis for corneal ectasia after LASIK. *Ophthalmology.* 2003;110(2):267-275



24. Hamada S, Barua A, Caporossi A, et al. Corneal crosslinking in children. In: Sinjab MM, Cummings A, eds. Corneal Collagen Crosslinking. Cham, Switzerland: Springer; 2017:229-268
25. Hashemi H, Atefi A, Khabazkhoob MJ. Effect of keratoconus grades on the repeatability of keratometry readings: comparison of 5 devices. J Cataract Refract Surg. 2015;41(5):1065-1072
26. Chan SP, Ang M, Saad A, et al. Validation of an objective screening algorithm for keratoconus and ectasia risk in Asian eyes. Cornea. 2015;34(9):996-1004