



PROPERTIES OF THE LIVER DURING PREGNANCY IN EXPERIMENTAL CHRONIC RENAL FAILURE

Rakhmonkulova Nargiza Gofurovna
Nuriddinova Saodat Fazliddinovna

Abu Ali ibn Sina renamed Bukhara State Medical Institute, Bukhara
Regional Perinatal Center, Uzbekistan.

Department of Obstetrics and Gynecology N2

4th year student of the Faculty of Medicine of Turkey, Bukhara State
Medical Institute named after Abu Ali ibn Sino
<https://doi.org/10.5281/zenodo.11396318>

ARTICLE INFO

Qabul qilindi: 20-May 2024 yil

Ma'qullandi: 25-May 2024 yil

Nashr qilindi: 30-May 2024 yil

KEY WORDS

*Liver morphometric indicators,
liver pathologies, experimental
chronic kidney failure.*

ABSTRACT

The treatment of liver pathologies in chronic renal failure observed during pregnancy worldwide and the prevention of their consequences remain a medical and social problem. Despite the development of methods of prevention and diagnosis, treatment of liver diseases, mortality rates continue to occupy a leading position. In our country, special attention is currently being paid to improving the social protection and health care system of the population, improving the quality of diagnosis, treatment and prevention of chronic liver diseases.

In some cases, based on morphological changes in internal organs, methods of differential diagnosis of the immediate cause of complications have been developed, each of which can have several consequences for the body at once, which can lead to death. The installation of such experiments is unthinkable without knowledge of the morphological and morphometric parameters of laboratory animals, which is an important part of the model experiment and remains poorly understood to this day.

Introduction. Studying the normative morphological and morphometric indicators of the liver of fetal white-breed rats in the laboratory, determining the anatomical parameters of the liver in the fetus its experimental reactive changes after chronic kidney failure, comparing the fetal – dependent histo-topographic characteristics of the liver of white-breed rats with indicators of healthy rats in experimental chronic kidney failure; an experimental study of the comparative classification of morphometric changes in the liver of fetal rats after correction with juicer water in chronic kidney failure was carried out.

The tasks of the study consist of those in the well: 1. Study of normative morphological and morphometric indicators of the liver of fetal white-breed rats;

2. Study of the anatomical parameters of the liver of white-breed rats in the fetus and its reactive changes after experimental chronic kidney failure;

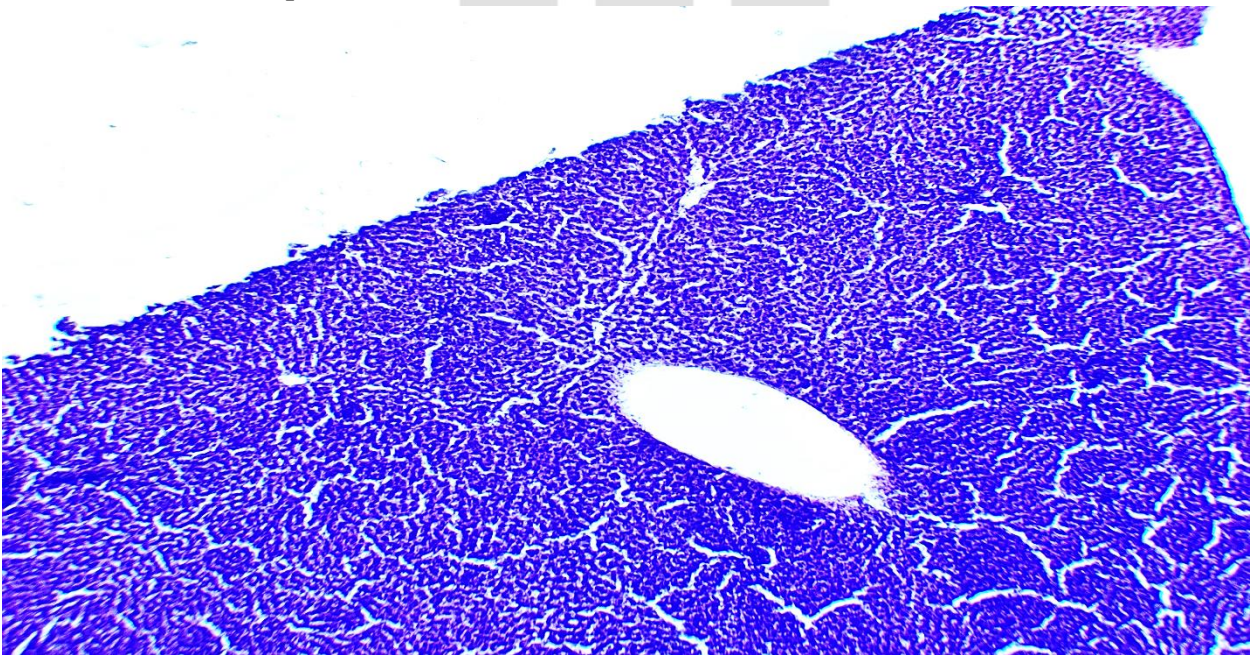
3. Comparison of fetal –dependent histo-topographic characteristics of the liver of white-breed rats with indicators of healthy rats in experimental chronic kidney failure;
4. Comparative classification of morphometric changes in the liver of fetal rats after correction with juicer waters in experimental chronic kidney failure.

I will give us an example of what was done before the experiment. Direct injection of embryonic cells provides a quick tool for epithelial differentiation and tubulogenesis to develop the necessary stages, including the compound complex and the assembly of the basal membrane. In addition, grafting techniques have been studied that allow the study of embryonic renal vascularization and the effects of endothelial cells on differentiating embryonic cells. (Steenhard, Brooke M -2021).

There has been a study of a significant correlation between high consumption of fatty foods in white rats and structural changes in the kidney, such as decreased glomeruli number density, deformities, significant expansion of renal vessels and tubules, glomerular necrosis and atrophy, and thickening of the basal membrane. (Muhammed eyüp Altunkaynak, Elvan Ozbek, Berrin Zuhale Altunkaynak, Ismail San, Deniz Unal and Bunyami Unal-2020).

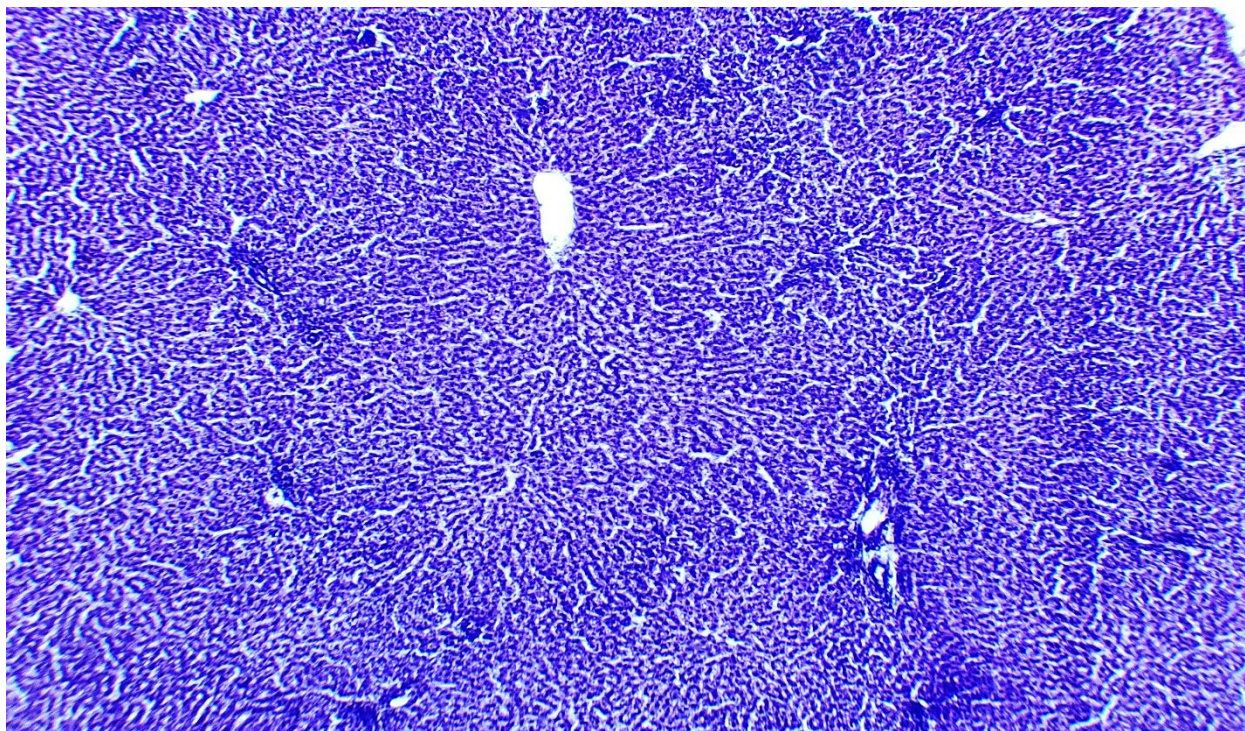
The purpose of the scientific work: to study the post-chronic renal failure changes in morphological and morphometric indicators of the liver of fetal rats without a white breed

Results from the experiment:



Morphological structure of liver tissue. Paint G-E. EU 10x10 ok.

1. Deformation of the central venous wall (sclerotic changes) and narrowing of the cavity .
2. Perenchymatous protein (hydropic and hyaline droplet) dystrophy in hepatocytes. hepatocytes-the nucleus is painted with a reduced basafil in the center, the cytoplasm of which is occupied by vacuoles (droplets) of different sizes).
3. Elastic-fibrosis tissue and polymorphic cell inflammatory infiltrate in the Portal tract.
4. The cavity of the Sinusoid cavity and perisinusoid area (Disse) is enlarged swelling.



Morphological structure of liver tissue. Paint G-E. EU 10x10 ok.

1. Deformation of the wall of the vein and artery of the hepatic triad (sclerotic changes) and narrowing of the cavity ,around inflammatory infiltrate.
2. Perenchymatous protein (hydropic and hyaline droplet) dystrophy in hepatocytes. hepatocytes-the nucleus is painted with a reduced basafil in the center, the cytoplasm of which is occupied by vacuoles (droplets) of different sizes).
3. Elastic-fibrosis tissue and polymorphic cell inflammatory infiltrate in the Portal tract.
4. The cavity of the Sinusoid cavity and perisinusoid area (Disse) is enlarged swelling.

Conclusion. Chronic kidney failure" chronic glomerulonephritis " is a consequence of all glomerulopathies : acute glomerulosclerosis , membranous and membranous-proliferative glomerulonephritis. In this case , the kidneys are symmetrically defined by the fact that they do not budge, the surface remains granular. In our experiment , the following changes were detected when the expressive chronic deficiency in white-breed rats was deciphered and microscopic examination of the changes in it was carried out. Shrinkage of the size of the glomeruli , sclerotic (in dimensions)changes, the onset of hyalinosis , enlarged cavity, infiltration. It is determined that narrowing of the Afferent and efferent arterioles, disruption of blood circulation between them, leads to secondary damage to the balls. The Shmulyansky-Bauman capsule is thickened. Ischemic processes have been found to cause focussed cariolysis, cariorexis, in the nucleus of the distal and proximal curved-bugrian epithelium, protein (hydropic and hyaline droplet) dystrophy in the cytoplasm , swelling in interstitial-intermediate tissue, fibrosis causing thickening of tissue. It was found that the wall of the middle and small-caliber arteries thickened , and narrowing of the blood flow path led to secondary hypertension and atrophy of the renal parenchyma. Rats in the same group studied the anatomical and morphological changes that occur in the liver during pregnancy. When the liver is macroscopic , the size is enlarged , the surface is smooth, the capsule is reminiscent of tense nutmeg. When examined microscopically: deformation of the central venous wall

(sclerotic changes) , fullness and narrowing of the cavity (in dimensions), inflammatory infiltrate around. Perenchymatous protein (hydropic and hyaline droplet) dystrophy in hepatocytes. hepatocytes-the nucleus is painted with a reduced basophil in the center, the cytoplasm of which is occupied by vacuoles (droplets) of different sizes. We can see that the uneven fat(drops) of hepatocytes located at the edges of the liver fragments press - fatty dystrophy has developed.The cavity of the Sinusoid cavity and perisinusoid area (Disse) is enlarged ,swelling.metabolism is evident in the fact that processes are slow, while the numerical increase in bi-nuclear hepatocytes is evident in the decompensation process.

References:

1. Ибраимова, Х. Р. (2019). Нурллаев Руслон Рустамбекович, Артиков Икром Ахмеджанович Влияние паразитарных болезней на особенности развития туберкулеза у детей, проживающих в Хорезмской области. Наука, техника и образование, 9, 62.
2. Облокулов, А. Р., Ниязова, Т. А., Мирзажанова, Д. Б., & Нуруллаев, Р. Р. (2014). Клиническая эффективность применения экдистена при первично хроническом бруцеллезе. Инфекция иммунитет и фармакология, (3-2), 32.
3. Машарипова, Ш. С., Ибраимова, Х. Р., Нурллаев, Р. Р., & Садуллаев, С. Э. (2023). ТЕЧЕНИЕ ВНУТРИБОЛЬНИЧНЫХ ПНЕВМОНИИ У БОЛЬНЫХ НАХОДЯЩИХСЯ НА ДЛИТЕЛЬНОМ АППАРАТЕ ИСКУССТВЕННОЙ ВЕНТИЛЯЦИИ ЛЁГКИХ. Scientific Impulse, 2(16), 1172-1178.
4. Ибраимова, Х. Р., Нурллаев, Р. Р., & Артиков, И. А. (2020). ВЫЯВЛЕНИЕ ТУБЕРКУЛЕЗА В ХОРЕЗМСКОЙ ОБЛАСТИ. Наука и образование сегодня, (6-1 (53)), 83-84.
5. Ибраимова, Х. Р., Нурллаев, Р. Р., & Артиков, И. А. (2019). Влияние паразитарных болезней на особенности развития туберкулеза у детей, проживающих в Хорезмской области. Наука, техника и образование, (9 (62)), 68-72.
6. Ibraximova, H. R., Nurllayev, R. R., & Matyaqubova, O. U. (2023). KICHIK YOSHDAGI BOLALAR ORASIDA ICHAK PARAZITAR KASALLIKLARINING EPIDEMIOLOGIK XUSUSIYATLARI. Новости образования: исследование в XXI веке, 2(15), 109-114.
7. Nurllayev, R. R., Ibadullayeva, S. S., & Yoqubov, Q. Y. (2023). KICHIK QON AYLANISH DOIRASI ARTERIYALARINING MORFOLOGIK TUZILISHI. Научный Фокус, 1(8), 463-468.
8. Sadullayev, S. E., Matyakubova, O. U., Artikov, I. A., Nurllayev, R. R., Ibadullayeva, S. S., & Yakubov, K. Y. (2023). RESULTS OF STUDIES ON THE LEVEL OF POPULATION KNOWLEDGE ABOUT PARASITIC DISEASES AND ITS PREVENTION. Western European Journal of Medicine and Medical Science, 1(4), 15-20.
9. Ibadullayeva, S. S., Yakubov, K. Y., Artikov, I. A., Nurllayev, R. R., & Sadullayev, S. E. (2023). CHARACTERISTICS OF PATHOMORPHOLOGICAL CHANGES IN LYMPHOCYTIC LEUKOSIS IN CHILDREN. Western European Journal of Medicine and Medical Science, 1(4), 21-26.
10. Nurillaev, R. R., & Matyakubova, O. U. (2023). EPIDEMIOLOGICAL STRUCTURES OF DIARRHEAL DISEASES IN THE KHOREZM REGION. PEDAGOG, 6(2), 126-129.
11. Ibrakhimova, H. R., & Nurllayev, R. R. (2023). A METHOD FOR OBTAINING PRECIPITATING SERUMS FOR THE DETECTION OF HUMAN SEMINAL FLUID USED IN THE STUDY OF PHYSICAL EVIDENCE IN FORENSIC BIOLOGICAL LABORATORIES. World Bulletin of Management and Law, 19, 42-44.
12. Djalilovna, A. M., Nurullaev, R. R., KB, T. S. A. S., & Rakhimova, M. (2022). Chronic viral hepatitis b in women of reproductive age living in the aral sea region.

13. Юсупов, Ш. Р. (2021). НУФУРОКСАЗИД-АНТАГОНИСТИЧЕСКИЙ АКТИВНЫЙ ПРОБИОТИК НА МИКОБАКТЕРИИ ТУБЕРКУЛЕЗА. In Инновационные технологии, экономика и менеджмент в промышленности (pp. 17-21).
14. Рузибаев, Р. Ю., Юсупов, Ш. Р., & Сапаева, Ш. А. (2021). МЕРЫ ДЛЯ СНИЖЕНИЯ КОРРУПЦИИ В СФЕРЕ ВЫСШЕГО ОБРАЗОВАНИЯ И МЕДИЦИНЫ. In Инновационные технологии, экономика и менеджмент в промышленности (pp. 227-229).
15. Нуралиев, Н. А., Нуралиева, Х. О., & Юсупов, Ш. Р. (2014). О" Программе мер по ликвидации последствий высыхания Арала и предотвращение катастрофы экосистем в Приаралье". Журнал теоретической и клинической медицины, (4), 43-45.
16. Юсупов, Ш. Р., Аитов, К. А., Савилов, Е. Д., Абдуллаева, Д. К., & Умиров, С. Э. (2023). Этиологическая характеристика хронических вирусных Гепатитов в хорезмской области узбекистана. Байкальский медицинский журнал, 2(2).
17. Юсупов, Ш. Р., Аскарлова, Р. И., Машарипова, Ш. С., & Якубова, У. Б. (2019). Анализ факторов риска, влияющих на развитие туберкулеза у детей в Хорезмской области. Наука, техника и образование, (8 (61)), 66-72.
18. Аскарлова, Р. И., & Юсупов, Ш. Р. (2023). Технологии обучения и образовательная деятельность студентов в медицинских ВУЗах. Наука, образование и культура, (1 (64)), 33-36.
19. Облокулов, А. Р., Нарзиев, И. И., Холов, У. А., Ниязов, Г. Э., & Юсупов, Ш. Р. (2018). Особенности течения кишечного лямблиоза у взрослых. Новый день в медицине,(1), 21.
20. Аскарлова, Р. И., Юсупов, Ш. Р., Хасанова, М. Ф., & Атаджанова, О. Н. (2023). Основные меры профилактики населения Приаралья от туберкулеза для детей и подростков. Проблемы современной науки и образования, (7 (185)), 42-47.

INNOVATIVE
ACADEMY