



MORPHOLOGICAL ANALYSIS OF CHANGES IN THE KIDNEYS DURING THE ACUTE AND SUB-ACUTE PERIOD OF SEVERE BRAIN INJURY.

Khuseynova Gulshan Khuseynovna

Bukhara State Medical Institute, Department of Anatomy, Clinical Anatomy (OSTA).

<https://doi.org/10.5281/zenodo.10431887>

ARTICLE INFO

Qabul qilindi: 20-December 2023 yil
Ma'qullandi: 23- December 2023 yil
Nashr qilindi: 26- December 2023 yil

KEY WORDS

traumatic brain injury, kidneys, nephron, biopsy, Shumlyansky-Bowman's capsule, vascular glomerulus.

ABSTRACT

This article provides information on the results of assessment of the morphological features of 3-month rats and morphological features due to a severe head of brain. Morphological analysis of rats of rats was conducted in the 1st, 3st and 7rd day after the brain injury.

Abstract: During the rapid development of technical development in the world, the formation of brain injuries and subsequent complications, among other injuries, has become an urgent problem at the level of the state and society [7,11,16,21,33,36,37,48.]. It can be seen in a number of studies that it gained great importance especially at the end of the 20th century [1,4,7,10,18,19,32,34,38,41.].

Among a number of injuries, traumatic brain injury (TBI) is one of the main problems in the health care system and social importance of any country due to its frequent occurrence and serious complications [3,6,8,12,14,17,30,34,35 .]. It is also one of the main causes of human death compared to other injuries. Although head injury is not inferior to cardiovascular, oncological and infectious diseases, it is far ahead of them in terms of premature death [13,15,20,23,26,43.]. Brain injuries are reported to be 10 times more likely to cause death after cardiovascular disease and 20 times more than death after cancer among individuals aged 30-40 years [5,27,31,35,40,49]. Traumatic brain injury is the leading cause of death and disability among the population under 45 [1,4, 24,28,32,42,44,50.].

Brain damage does not affect the functioning of the kidneys. The kidney performs many tasks in the human body and actively participates in almost all types of metabolism , maintaining homeostasis in the body . participates . There are different types of kidneys It serves as an important link in the formation of adaptive reactions in the body in response to the effects of the external environment , in response to changes that occur after pathological processes in other organs and systems [25,29,33,45,46,51 .].

is one of the important organs that are subjected to intensive functional stress under the influence of any external factors during human life [2,9, 30,39,47,52] .

In this direction, secondary extraspinal complications after traumatic brain injury, in particular, in modern nephrology, rarely

achieve positive results in the treatment and improvement of the quality of kidney diseases, which in turn requires the development of new evidence-based methods of treatment for specialists in this field.

Materials and methods: Three-month-old white rats with an average weight of 150 g were obtained for this study. All laboratory animals were housed in a vivarium in plastic cages lined with wood chips at room temperature with a 12-h light-dark cycle, in accordance with laboratory animal care standards. The animals of the experimental group were divided into 2 groups, i.e., the first group included animals without spinal cord injury (control, n=5), and the second group (experimental n=5) included animals with mild spinal cord injury. In the study, mild spinal cord injury was induced in white rats in a specially designed model using the "traffic accident" technique.

During this experiment, all animals suffered mild to severe injuries. After the injury, the surviving animals were transferred to a special plastic cage and observed until recovery of the post-traumatic condition.

Results of the study: In the analysis of changes in the kidney of 3-month-old white rats after severe brain injury, the following data were obtained: macroscopically, the kidneys of 3-month-old white rats of the experimental group are bean-shaped, It is located in the lumbar region and is covered with a smooth and shiny capsule from the outside, macroscopically other than the increase in volume, other visible pathological changes were not detected (Table 1).

Table 1

Comparative description of histomorphometric parameters in kidney nephrons after severe brain injury.

Kidney elements from BMSH next days	The average area of the renal corpuscle (μm^2)	Mean diameter of the distal tubule (μm)	Mean outer diameter of the proximal tubule (μm)
The norm	1993,04 ± 23,2	27,61 ± 0,2	31,1 ± 0,9
Day 1	2305,96 ± 29,9	30,09 ± 0,5	33.12 ± 0.8
Day 3	2309,39 ± 24,0	30,19 ± 0,4	33.19 ± 0.8
Day 7	2313,41 ± 22,4	30,35 ± 0,7	33.32 ± 0.6

In the process of research Body weight of three-month-old white rats with severe brain damage in experimental group 2 is from 130 g to 178 g, with an average of 156 g. it was

noted that it is in the range.

The changes of morphological and morphometric parameters of the kidneys of rats on the 1st day after severe brain damage were shown in the dynamics of UV transmission as follows: the absolute weight of the kidneys - from 852.52 mg to 1388.77 mg, the average weight - $1059.96 \pm 54,6$ mg; kidney length - from 16.72 to 21.52 mm, average length - 19.3 ± 0.3 mm; width - from 6.15 mm to 8.98 mm, average width - 7.57 ± 0.3 mm; thickness - from 5.51 mm to 9.54 mm, average thickness - 7.24 ± 0.4 mm; the volume of the right kidney ranged from 364.37 mm^3 to 962.182 mm^3 , the average was $552.02 \pm 43.3 \text{ mm}^3$.

The area of kidney bodies - from $2169.6 \text{ }\mu\text{m}^2$ to $2399.87 \text{ }\mu\text{m}^2$, average - $2305.96 \pm 19.4 \text{ }\mu\text{m}^2$; the area of the vascular ball - from $1766.3 \text{ }\mu\text{m}^2$ to $2012.91 \text{ }\mu\text{m}^2$, on average - $1910.01 \pm 21.8 \text{ }\mu\text{m}^2$; the area of the capsule cavity ranged from - $326.32 \text{ }\mu\text{m}^2$ to $386.23 \text{ }\mu\text{m}^2$, the average was equal to - $349.63 \pm 5.1 \text{ }\mu\text{m}^2$.

The diameter of the proximal convoluted tubules is from 29.66 to 38.12 μm , the average is $33.12 \pm 0.7 \text{ }\mu\text{m}$, the diameter of the tubular space is from 15.2 to 25.39 μm , the average is 18, It was equal to $1 \pm 0.7 \text{ }\mu\text{m}$.

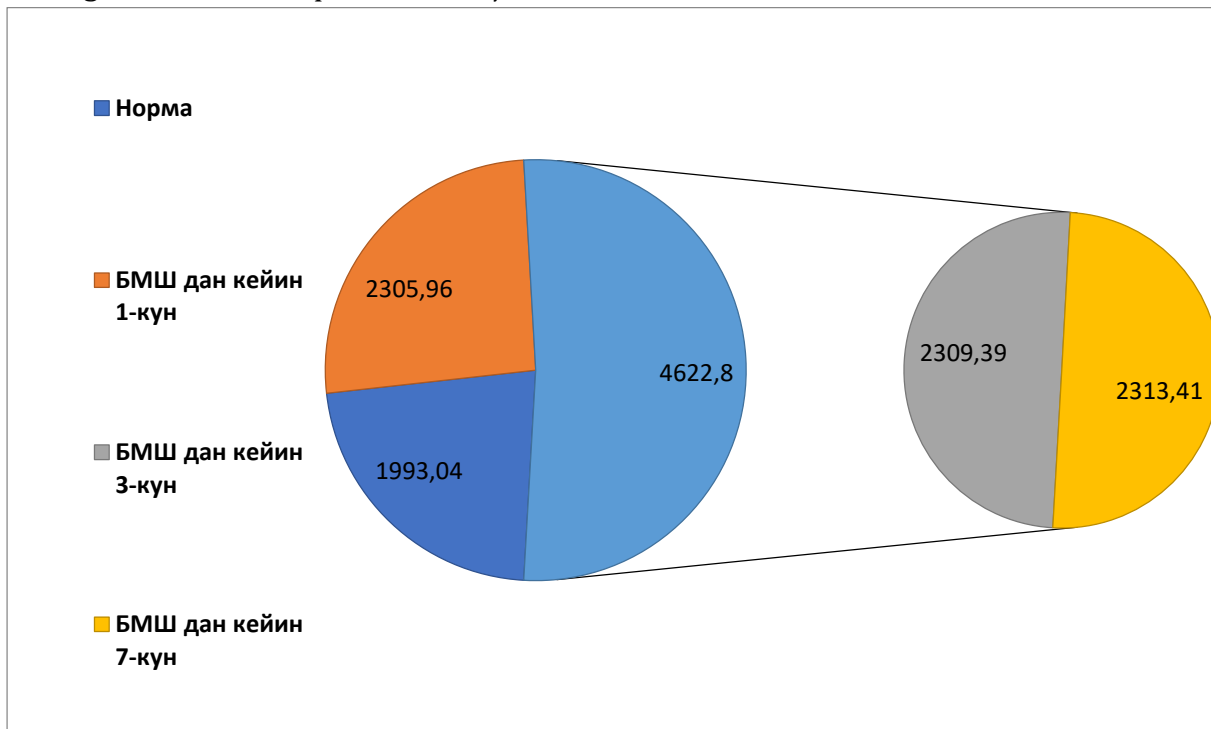


Figure 1. Comparative description of histomorphometric parameters of renal nephron elements on the 1st, 3rd, and 7th day after severe brain injury.

The diameter of the distal convoluted tubular tubules is from 26.36 μm to 32.9 μm , the average is $30.09 \pm 0.6 \text{ }\mu\text{m}$, the diameter of the tubular space is from 14.1 μm to 18.31 μm , the average is 16, It was equal to $2 \pm 0.4 \text{ }\mu\text{m}$ (Fig. 1).

Changes in morphological and morphometric indicators of rat kidneys three days after severe brain damage were shown as follows: the absolute weight of kidneys increased from 917.3 mg to 1275.62 mg, the average weight increased from 1077.99 ± 32.2 mg, kidney length - from 16.52 mm to 21.67 mm, average length - 18.66 ± 0.6 mm; width - from 6.69 mm to 9.8 mm, average width - 7.91 ± 0.3 mm; thickness - from 5.88 mm to 8.92 mm, average thickness - 7.22 ± 0.3 mm; the volume of the right kidney ranged from 354.6 mm^3 to 700.84 mm^3 , the average was equal to $555.83 \pm 31.3 \text{ mm}^3$.

The area of kidney bodies is from $2185.86 \mu\text{m}^2$ to $2413.8 \mu\text{m}^2$, the average is $2309.39 \pm 24.0 \mu\text{m}^2$; the area of the vascular ball is from $1689 \mu\text{m}^2$ to $2179 \mu\text{m}^2$, the average value is $1923.72 \pm 39.5 \mu\text{m}^2$, the area of the capsule cavity is from $311.5 \mu\text{m}^2$ to $389.2 \mu\text{m}^2$, the average is 354.48 It was found to be $\pm 6.5 \mu\text{m}^2$.

The diameter of the proximal convoluted tubules is from $30.64 \mu\text{m}$ to $39.46 \mu\text{m}$, the average is $33.19 \pm 0.8 \mu\text{m}$, the diameter of the tubular cavity is from $15.76 \mu\text{m}$ to $24.92 \mu\text{m}$, the average is 18 , It was equal to $17 \pm 0.8 \mu\text{m}$.

The diameter of the distal convoluted tubules is from 28.12 to $32.38 \mu\text{m}$, the average is $30.19 \pm 0.4 \mu\text{m}$, the diameter of the tubule cavity is from 14.87 to $17.83 \mu\text{m}$, the average is 16 , It was equal to $22 \pm 0.3 \mu\text{m}$.

Changes in the morphological and morphometric parameters of the kidneys of rats seven days after severe brain damage were shown as follows: the absolute weight of the kidneys was from 734.52 mg to 1267.76 mg , the average weight was $1090.04 \pm 51.2 \text{ mg}$; kidney length - from 17.66 mm to 20.98 mm , average length - $19.02 \pm 0.3 \text{ mm}$; width - from 5.75 mm to 9.46 mm , average width - $7.59 \pm 0.3 \text{ mm}$; thickness - from 5.46 mm to 9.32 mm , average thickness - $7.47 \pm 0.3 \text{ mm}$; kidney volume - from 380.1 mm^3 to 751.71 mm^3 , average - $565.75 \pm 36.3 \text{ mm}^3$.

The area of kidney bodies is from $2187.4 \mu\text{m}^2$ to $2425.32 \mu\text{m}^2$, the average is $2313.4 \pm 22.4 \mu\text{m}^2$; the area of the vascular ball - from $1687.75 \mu\text{m}^2$ to $2278.5 \mu\text{m}^2$, on average - $1937.47 \pm 46.7 \mu\text{m}^2$; it was noted that the area of the capsule cavity is $327.2 \mu\text{m}^2$ to $427.67 \mu\text{m}^2$, the average is $370.66 \pm 7.2 \mu\text{m}^2$.

The diameter of the proximal convoluted tubules is from $30.38 \mu\text{m}$ to $37.1 \mu\text{m}$, the average is $33.316 \pm 0.6 \mu\text{m}$, the diameter of the tubular space is from $15.88 \mu\text{m}$ to $19.92 \mu\text{m}$, the average is $18.21 \pm$ It was $0.4 \mu\text{m}$.

The diameter of the distal convoluted tubular tubules is from $24.76 \mu\text{m}$ to $33.11 \mu\text{m}$, the average is $30.35 \pm 0.7 \mu\text{m}$, the diameter of the tubule cavity is from $13.71 \mu\text{m}$ to $19.77 \mu\text{m}$, the average is 16 , It was $39 \pm 0.5 \mu\text{m}$.

Conclusion: Thus, as a result of macroscopic, histological and histomorphometric studies, severe brain damage of the experimental group received A number of morphological changes were detected in the kidneys of 3- month-old white rats. especially Maximal changes were obtained in the experimental group with severe head injury significant changes were observed in the structure of kidney nephrons of white rats, and statistically significant differences were found in all studied indicators compared to the indicators of the control group of animals.

References:

1. Ataeva, M. A., & Baratova, M. (2021). Diagnosis of heart rhythm disorders at early stages of left ventricular remodeling. Central Asian Journal of Medical and Natural Science, 2(3), 107-112.
2. Atayeva, M. A. (2020). Cardiomyopathy as a Manifestation of Complications of Chronic Viral Hepatitis. American Journal of Medicine and Medical Sciences, 10(4), 258-261.
3. Atoeva, M. (2023). EPIDEMIOLOGICAL FEATURES OF INFLUENZA AND SARS DURING THE CORONAVIRUS INFECTION PANDEMIC. JOURNAL OF HEALTHCARE AND LIFE-SCIENCE RESEARCH, 2(5), 71-77.
4. ATOEVA, M. A., BARATOVA, M. S., & Jumamuratova, B. S. (2021). PREVALENCE OF VIRAL

- HEPATITIS" B" AND" C" AMONG MEDICAL WORKERS. Journal of natural remedies, 22(1 (2)), 54-59.
5. Atoeva, M. A., Baratova, M. S., Kobilova, G. A., & Hakimov, T. B. (2022). Predictive Models For Efficient Commerce Management In A Virtual Environment. Journal of Positive School Psychology, 6(7), 5190-5198.
6. ATOEVA, M., & Baratova, M. S. (2021). JUMAMURATOVA BS PREVALENCE OF VIRAL HEPATITIS" B" AND" C" AMONG MEDICAL WORKERS. Journal of natural remedies, 22(1), 2.
7. Atoeva, M., & Khayitov, A. (2022). Peculiarities of influenza virus circulation during the coronavirus pandemic. Scientific Collection «InterConf», (127), 162-163.
8. Atoyeva, M. A., & Jumamuratova, B. S. (2021). Psychoemotional factors related to COVID-19 quarantine. апрель-июнь, 98.
9. Baratova, M. S., Ataeva, M. A., & Berdiev, U. A. (2022). Sars and Influenza in the Formation of Complications Heart Rhythmthe. AMALIY VA TIBBIYOT FANLARI ILMIY JURNALI, 1(2), 15-20.
10. Baratova, M. S., Ataeva, M. A., Yuldasheva, S. T., & Vohidov, U. G. (2020). Periodontal diseases in military age persons and arterial hypertension. Asian Journal of Multidimensional Research (AJMR), 9(4), 111-113.
11. BARATOVA, M. S., ATAYEVA, M. A., & HALIMOVA, D. S. (2020). Modern Ultrasound Methods for Assessing Indicators of The Latent Diastolic Function of The Left Ventricle. International Journal of Pharmaceutical Research (09752366), 12(3).
12. Gulshan Khuseynovna Khuseynova. (2021). EVALUATION OF MORPHOLOGICAL CHANGES OF THE KIDNEYS IN CEREBRAL TRAUMA . Journal of Natural Remedies, 22(1(2)), 87-94.
13. Kabilova, G. (2021). General incidence with temporary loss of employment in silk milling plants. InterConf.
14. Kh, G. (2021). Khuseynova. Macroscopic and microscopic characteristics of kidneys of white unbored rats after severe cranial injury. The Doctor's Newsletter, (1), 98.
15. Kh, K. G., & Sh, T. (2020). Zh.//" Comparative characteristics of the morphometric parameters of the kidneys in different phases of traumatic brain injury.". Tibbietda yangi kun-2020, 2(1), 30.
16. Kh, K. G., & Sh, T. (2021). Zh. Morphological features of the kidneys in conditions of experimental traumatic brain injury. Problems of Biology and Medicine, (1), 125.
17. Khuseynova Gulshan Khuseynovna. (2022). ASSESSMENT OF MORPHOLOGICAL CHANGES IN THE KIDNEYS IN EASY DEGREE OF ACUTE PERIOD OF CRANIO-BRAIN INJURY. "ONLINE - CONFERENCES" PLATFORM, 307-308.
18. Kobilova, G. (2021). Modernization of production is a decisive factor of reducing the incidence of diseases in silk industries. InterConf.
19. Toirovna, Y. S. (2022). Integrative education of university students. BARQARORLIK VA YETAKCHI TADQIQOTLAR ONLAYN ILMIY JURNALI, 2(3), 73-77.
20. Toyirovna, Y. S. (2022). The importance of integrative and creative capabilities of students of medical institutes. BARQARORLIK VA YETAKCHI TADQIQOTLAR ONLAYN ILMIY JURNALI, 2(1), 450-462.
21. Toyirovna, Y. S. (2022). The importance of integrative and creative capabilities of students of medical institutes. BARQARORLIK VA YETAKCHI TADQIQOTLAR ONLAYN ILMIY

JURNALI, 2(1), 450-462.

22. Toyirovna, Y. S. (2022). TRANSFORMATION OF CREATIVE THINKING OF MEDICAL STUDENTS. EUROPEAN JOURNAL OF MODERN MEDICINE AND PRACTICE, 2(11), 55-58.

23. Toyirovna, Y. S. (2023). COMPLEX INTEGRATIVE-CREATIVE ACTIVITY IN THE EDUCATIONAL PROCESS. JOURNAL OF INNOVATIONS IN SCIENTIFIC AND EDUCATIONAL RESEARCH, 6(3), 5-9.

24. Toyirovna, Y. S. (2023). INNOVATIVE DEVELOPMENT IN EDUCATION. Новости образования: исследование в XXI веке, 1(8), 215-219.

25. Zhumaeva, A. A. (2023). STUDY OF SANITARY AND HYGIENIC LABOR CONDITIONS IN CARPET PRODUCTION. EUROPEAN JOURNAL OF MODERN MEDICINE AND PRACTICE, 3(3), 65-68.

26. Атаева, М. А. ПЛАНОВАЯ ИММУНИЗАЦИЯ-УДАР ПО ИНФЕКЦИЯМ. In Материалы межвузовской научно-практической конференции «Актуальные вопросы медицины», инициированной ЮЖНО-КАЗАХСТАНСКОЙ МЕДИЦИНСКОЙ АКАДЕМИЕЙ И ШЫМКЕНТСКИМ МЕДИЦИНСКИМ ИНСТИТУТОМ МЕЖДУНАРОДНОГО КАЗАХСКО-ТУРЕЦКОГО УНИВЕРСИТЕТА ИМЕНИ ХА ЯСАУИ (р. 30).

27. Атаева, М. А., Баратова, М. С., & Кобылова, Г. А. (2019). Вирусные гепатиты, осложненные кардиомиопатиями. Новый день в медицине, 25(1), 91.

28. Атоева, М. А. (2020). Ограничительные меры во время эпидемий: исторический экскурс и проблемы настоящего времени. Монография, «BUXORO NASHR».

29. Атоева, М. А. (2022). Эпидемический Процесс При Новой Коронавирусной Инфекции (Covid-19) И Его Профилактика. Miasto Przyszłości, 28, 57-59.

30. Атоева, М. А. (2023). Острые Респираторные Вирусные Инфекции В Период Пандемии. Central Asian Journal of Medical and Natural Science, 4(2), 184-189.

31. Атоева, М. А., & Жумамуратова, Б. С. (2021). Эпидемиологическая Характеристика Covid-19. Central Asian Journal of Medical and Natural Science, 51-54.

32. Атоева, М. А., & Хайитов, А. Х. (2022). Грипп в условиях пандемии коронавирусной инфекции. Инфекция, иммунитет и фармакология, 4, 53-57.

33. Атоева, М. А., Хайитов, А. Х., & Хакимов, Т. Б. (2023). БАКТЕРИАЛЬНЫЕ КОИНФЕКЦИИ В ПЕРИОД ПАНДЕМИИ COVID-19. Finland International Scientific Journal of Education, Social Science & Humanities, 11(5), 90-98.

34. Баратова, М. С., & Атаева, М. А. (2015). Оценка ранней дисфункции миокарда у больных с пороговой артериальной гипертензией и артериальной гипертензией I-степени. Международный журнал прикладных и фундаментальных исследований, (8-2), 232-233.

35. Баратова, М. С., & Атаева, М. А. (2018). РОЛЬ ОРВИ И ГРИППА В ФОРМИРОВАНИИ ОСЛОЖНЕНИЙ СЕРДЕЧНО-СОСУДИСТЫХ ЗАБОЛЕВАНИЙ. Редакционная коллегия, 35.

36. Баратова, М. С., Атаева, М. А., & Махмудова, М. Р. (2021). Диагностика коронавирусной инфекции при сердечно-сосудистой патологии и особенности течения карантина при Covid-19. Биология и интегративная медицина, (3 (50)), 47-66.

37. Баратова, М. С., Атаева, М. А., & Худойдодова, С. Г. (2017). Допплерграфия в диагностики нарушений функции миокарда левого желудочка после перенесенных инфекционных состояний. Tibbiyotda yangi kun, 4, 84-87.

38. Баратова, М. С., Атаева, М. А., Жалолова, В. З., & Рахматова, М. Р. (2016).

Эффективность тиотриазолина при аритмиях. Вестник Совета молодых учёных и специалистов Челябинской области, 1(2 (13)), 4-6.

39. Баратова, М. С., Бакаев, И. К., Атаева, М. А., & Махмудова, М. Р. (2016). Чувствительность и специфичность показателей доплерографии в диагностике нарушений функции миокарда левого желудочка у больных с высоким нормальным артериальным давлением и мягкой артериальной гипертензией после перенесенных инфекционных состояний. *European research*, (6 (17)), 102-104.

40. Баратова, М. С., Бакаев, И. К., Атаева, М. А., & Махмудова, М. Р. 1Баратова Мехрибан Субиддиновна/Baratova Mehriban–кандидат медицинских наук, отделение кардиологии; 2Бакаев Илхом Курбанович/Bakaev Ilkhom–главный врач, Бухарский областной кардиологический диспансер; 3Атаева Машхура Абборовна/Ataeva Mashkhura–кандидат медицинских наук. *EUROPEAN RESEARCH: INNOVATION IN SCIENCE, EDUCATION AND TECHNOLOGY*, 102.

41. Баратова, М. С., Кличев, А. Х., Атаева, М. А., & Собиров, С. Н. (2017). Применение тиотриазолина при суправентрикулярных и желудочковых экстрасистолах у пациентов с высоким нормальным артериальным давлением и мягкой артериальной гипертензией после перенесенных инфекционных состояний. V съезд терапевтов Забайкальского края, 14-15 марта 2017 года, г. Чита [Электронный ресурс]: сборник научных трудов/Под общей ред. НВ Ларёвой; Читинская государственная медицинская академия.-Электрон. текстовые дан.-Чита: РИЦ ЧГМА, 2017.-1 электрон. опт. диск (CD-ROM)-Мин. систем. требования: IBM PS 100 МГц; 16 Мб RAM; Windows XP; AdobeReader Сборник содержит статьи и тезисы докладов работников Читинской государственной медицинс, 32.

42. Баратова, М., Атаева, М., Мансурова, М., Кобилова, Г., & Махмудова, М. (2016). Допплерографии в диагностике нарушений функции миокарда лж у больных с высоким нормальным артериальным давлением и мягкой артериальной гипертензией после перенесенных инфекционных состояний. *Журнал вестник врача*, 1(2), 13-15.

43. Баратова, М., Атаева, М., Мансурова, М., Сулейманов, С., Давлетова, С., Узакова, Н., & Суюнова, М. (2013). Дисплазия митрального клапана и её медикаментозное лечение. *Журнал проблемы биологии и медицины*, (1 (72)), 22-23.

44. Баратова, М., Атаева, М., Якубов, Ш., Мансурова, М., Саъдуллаева, Г., & Кобилова, Г. (2011). Оценка гемодинамических показателей у пациентов с синдромом дисплазии соединительной ткани сердца. *Журнал вестник врача*, 1(2), 55-56.

45. Кобилова, Г. А. (2022). Профилактика Развития Заболеваний Под Действием Вредных Факторов В Шелкомотальном Производстве «Бухара Бриллиант Силк». *AMALIY VA TIBBIYOT FANLARI ILMIY JURNALI*, 327-331.

46. Кобилова, Г. А. (2022). Эффективность Модернизации В защите Здоровья Работников Шелкомотального Производства. *AMALIY VA TIBBIYOT FANLARI ILMIY JURNALI*, 280-287.

47. Кобилова, Г. А., & Жумаева, А. А. (2018). Факторы риска развития внутрибольничных инфекций в акушерских стационарах Бухарской области. In Материалы межвузовской научно-практической конференции «Актуальные вопросы медицины», инициированной ЮЖНО-КАЗАХСТАНСКОЙ МЕДИЦИНСКОЙ АКАДЕМИЕЙ И ШЫМКЕНТСКИМ МЕДИЦИНСКИМ ИНСТИТУТОМ МЕЖДУНАРОДНОГО КАЗАХСКО-

ТУРЕЦКОГО УНИВЕРСИТЕТА ИМЕНИ ХА ЯСАУИ (р. 61).

48. Кобилова, Г. А., & Саломова, Х. Ж. (2020). Показатели здоровья рабочих в шелкоткальном производстве «бухара бриллиант силк». Новый день в медицине, (2), 407-408.

49. Юлдашева, Ш. (2021). Основные Тенденции Интегративно-Креативных Возможностей студентов в Высшем Медицинском учебном Заведении и их Влияние на их Деятельность. Central Asian Journal of Medical and Natural Science, 2(3), 369-377.

50. Юлдашова, Ш. Т. (2023). ИНТЕГРАТИВНО-КРЕАТИВНАЯ ДЕЯТЕЛЬНОСТЬ В ПРЕПОДАВАНИИ ПРЕДМЕТА ВАЛЕОЛОГИИ. Новости образования: исследование в XXI веке, 1(9), 719-724.

51. ЮЛДАШОВА, Ш. Т. ИССЛЕДОВАТЕЛЬСКАЯ ДЕЯТЕЛЬНОСТЬ КАК СФЕРА СТАНОВЛЕНИЯ КЛИНИЧЕСКОГО МЫШЛЕНИЯ БУДУЩЕГО ВРАЧА. EDAGOGIK ANORAT, 137.

52. Юлдашова, Ш., Кобилова, Г., Жумаева, А., Ражабова, Д., & Шарипова, Н. (2012). Организация деятельности и подготовка среднего медицинского персонала ранимационного отделения. Журнал проблемы биологии и медицины, (1 (68)), 168-171.



INNOVATIVE
ACADEMY